

НОВІ МЕТОДИ І ТЕХНОЛОГІЇ

UDC 616.728.3-089.843-77

DOI <https://doi.org/10.32782/2226-2008-2025-4-12>Yu. V. Sukhin <https://orcid.org/0009-0006-9366-6902>Yu. Yu. Pavlychko <https://orcid.org/0000-0003-0060-4536>B. R. Bovsunovskyi <https://orcid.org/0009-0006-3631-3633>APPLICATION OF THE NAVIGATION SYSTEM
IN PRIMARY TOTAL KNEE REPLACEMENT

Odesa National Medical University, Odesa, Ukraine

UDC 616.728.3-089.843-77

Yu. V. Sukhin, Yu. Yu. Pavlychko, B. R. Bovsunovskyi

APPLICATION OF THE NAVIGATION SYSTEM IN PRIMARY TOTAL KNEE REPLACEMENT

Odesa National Medical University, Odesa, Ukraine

It is difficult to imagine the modern world and medicine without the application of computer technologies, which significantly enhance doctors' work and improve its quality. These technologies positively impact the speed and accuracy of surgical interventions. Specifically, in knee arthroplasties, precise measurements and calculations are crucial for correctly implanting endoprotheses and avoiding postoperative complications to achieve favourable biomechanical outcomes.

The aim of the study was to compare experience of applying a modern computerised navigation system in identifying the actual resection levels of the femur and tibia during knee arthroplasty, with conventional methods experience.

Materials and methods. The *Orthopilot* navigation system, produced by the Aesculap company, was used at the Department of Traumatology, Orthopaedics, and Combat Trauma of Odesa National Medical University, based at the University Clinic. This system allows the real-time determination of the most optimal resection points for the femoral and tibial bones during 3D modelling of the surgical procedure. Surgery using a computed navigation system was performed on a 55-year-old female patient with grade III gonarthrosis underwent treatment and were examined postoperatively for six months. The study was conducted in accordance with the provisions of the Declaration of Helsinki, patient was informed about the objectives of the study and provided informed consent to participate in the study and the processing of her personal data.

Results. During the study, it was found that the installation of knee joint endoprosthesis using a computerized navigation system allows more accurate implant placement and helps to avoid imbalance of the knee joint ligaments and, despite the longer duration of the operation, is considered safe regarding blood loss and postoperative complications.

Keywords: knee joint endoprosthesis, navigation system, surgery, modern technology.

УДК 616.728.3-089.843-77

Ю. В. Сухін, Ю. Ю. Павличко, Б. Р. Бовсунівський

ЗАСТОСУВАННЯ НАВІГАЦІЙНОЇ СИСТЕМИ В ПЕРВИННОМУ ТОТАЛЬНОМУ ЕНДОПРОТЕЗУВАННІ КОЛІННОГО СУГЛОБА

Одеський національний медичний університет, Одеса, Україна

Сучасний світ і медицину неможливо уявити без використання та впровадження комп'ютерних технологій, які явно полегшують і покращують роботу лікарів, позитивно впливаючи на швидкість та точність виконання оперативних втручань. Зокрема, операція з ендопротезування колінного суглоба потребує точних вимірів і розрахунків для коректного встановлення імплантів та уникнення розвитку післяопераційних ускладнень, досягнення позитивних результатів з погляду біомеханіки руху.

У статті розглянуто клінічний випадок лікування пацієнтки з діагнозом «Гонартроз III ст.» на базі Університетської клініки ОНМедУ, використаний для порівняння досвіду використання комп'ютеризованої навігаційної системи з досвідом використання традиційних мануальних навігаційних систем.

Ключові слова: ендопротез колінного суглоба, навігаційна система, оперативне лікування, сучасні технології.

Introduction

It is impossible to imagine modern medicine without the application of computer technologies, as they have become an essential tool in many areas of medical practice.

The implementation of computer technologies has enabled high accuracy and speed in performing various diagnostic procedures and surgical interventions, particularly, in total knee arthroplasty, a complex radical and most effective surgical treatment for one of the most common musculoskeletal late diagnosed diseases – knee arthrosis [1–4]. Over the past decades, due to the development of technologies and surgical techniques, the frequency of knee replacement operations has increased significantly, and the

© Yu. V. Sukhin, Yu. Yu. Pavlychko, B. R. Bovsunovskyi, 2025

Стаття поширюється на умовах ліцензії



number of complications has decreased significantly. A further increase in the frequency of total joint arthroplasty operations is predicted [5]. It has been proven that high-quality arthroplasty of large joints of the lower extremities (hip and knee) has a positive effect on the quality of life of patients, however, about 30% of patients remain dissatisfied with the result, which is mainly due to the level of quality of the endoprosthesis installation operation [6]. In total knee arthroplasty, achieving the optimal conditions for implanting a knee endoprosthesis requires not only adherence to the surgical plan and adequate surgical skills [7], but also the ability to perform precise resections of the femur and tibia, accurate determination of the implant insertion depth, and correct rotational and axial alignment. These factors are critical for achieving ideal load distribution across the bone condyles and prosthetic components. Excessive or improper load distribution on the bone condyles may lead to prosthetic instability. Inaccurate osteotomies – whether in height or angle – increase the risk of joint instability, stiffness, or persistent postoperative pain [8]. It is essential to ensure accurate control of load distribution, depending on the type of deformity present. The instruments currently available for knee arthroplasty do not permit perfect bone resections; however, the precision of osteotomies remains a key determinant of success in knee replacement surgery [9].

The aim of the study was to compare the experience of applying a modern computerised navigation system in identifying the actual resection levels of the femur and tibia during knee arthroplasty, with conventional techniques.

Materials and Methods

The *Orthopilot* navigation system by the Aesculap company was used at the Department of Traumatology, Orthopaedics, and Combat Trauma of Odesa National Medical University, based at the University Clinic. This system allows the real-time determination of the most optimal resection points for the femoral and tibial bones during 3D modelling of the surgical procedure.

The navigation system used is a hardware-based navigation tool that facilitates the individualised positioning of implants during surgery. The video-camera system detects the position and orientation of passive sensors that reflect infrared light. These sensors are located on each cutting block, multitool, and on the femur and tibia. This setup enables real-time transmission of data about the resected segments in millimetres and degrees.

Specialised software installed on the navigation system, that was used, the computing and display unit calculates the spatial relationship and alignment of the sensors. The system also adapts to both surgical instruments and the patient's individual anatomical features, allowing real-time visualisation of instrument positioning in relation to the operated segment. This enables precise spatial placement of each implant component to optimise surgical outcomes.

Results

An operative treatment was performed on a 55-year-old female patient with grade III deforming osteoarthritis of the knee at the University Clinic of Odesa National Medical University in March 2021. The patient was informed about the objectives of the study and provided informed consent

to participate in the study and the processing of her personal data.

Surgical technique. The navigation system, that was used, does not require the use of additional high-intensity imaging techniques such as computed tomography. It operates as a closed system with its own proprietary software. The system includes the following components: tripod, wireless camera, personal panel computer, and a wireless foot switch.

During the surgery we followed the standard operation technique for using the computed navigation system of that type. To assess the biomechanical features of the knee joint, sensors are fixed to the patient's femur and tibia using pins at the start of the operation. The surgeon then performed knee movements, including maximum flexion and extension. The navigation display showed the dynamic deviation of the lower limb axis during flexion of the tibia (varus or valgus deformities) (Fig. 1).

Using a multitool (an instrument equipped with an infrared sensor that transmits information on the location of anatomical landmarks of the lower limb), the surgeon marked the lateral and medial malleoli, the lateral and medial femoral and tibial condyles, and the intercondylar eminence. This data was processed by the navigation system to determine the most effective and accurate resection planes and directions for the femoral and tibial components.

The system then schematically displayed the real-time position of the resection block in relation to the tibia, with tilt accuracy of up to 1 degree and resection height accuracy of up to 1 millimetre (Fig. 2).

After performing the tibial component resection, the system stored the level and direction of the resection to enable subsequent calculation of the femur-tibia ratio. Next, the femoral condyle points were identified and marked using the multitool (Fig. 3).

Once the femoral component size has been determined, the next step was to perform a collateral ligament stress test in both flexion and extension positions of the knee (Fig. 4).

The following step involved determining the extent of femoral resection required for optimal placement of the endoprosthesis components (Fig. 5). At this stage, the surgeon can make adjustments to improve component positioning, such as: preventing the femoral component from impinging on the anterior cortical bone by modifying its flexion angle; avoiding the formation of joint laxity or stiffness following implantation of all prosthetic components by adjusting the femoral resection height; selecting the appropriate angle and optimal rotation of the femoral component to ensure correct load distribution.

Clinical case. Patient S., a 55-year-old female, was diagnosed with grade III deforming gonarthrosis of the right knee and treated at the Department of Traumatology, Orthopaedics, and Combat Trauma of Odesa National Medical University, based at the University Clinic.

Following clinical and radiological examinations, as well as consultations with relevant specialists, the patient underwent primary total cemented right knee arthroplasty using the computed navigation system. Intraoperative and postoperative X-ray control was performed (Fig. 6). Blood loss was 450 ml, which does not exceed the average for knee

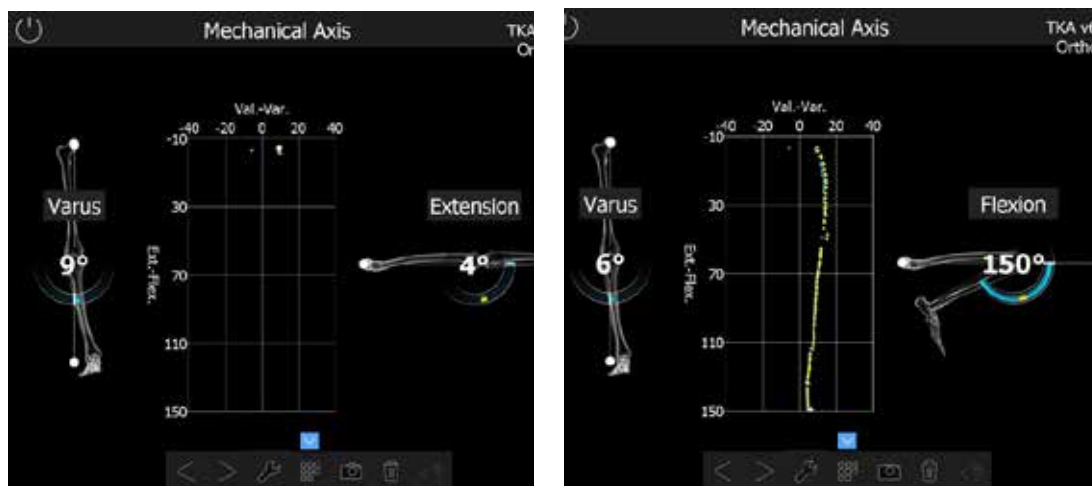


Fig. 1. Intraoperative determination of mechanical axis of the extremity in the knee joint using computed navigation system sensors

arthroplasty operations using traditional navigation systems (329–1517 ml), the duration of the operation was 142 min, which exceeded the average duration (118 ± 20 min) for operations using traditional navigation systems [10].

On the first day after surgery, the patient began both passive and active movements of the operated joint, sitting on the bed. On the second day, she got out of bed and walked around the room, and by the fourth day, she was walking down the hallway. Discharged from the hospital on the sixth day after surgery. The timing of the acute rehabilitation period corresponds to average values for knee arthroplasty using traditional navigation systems. She subsequently completed a full course of physiotherapy aimed at restoring the function of the right knee joint.

At the follow-up examination 1.5 months after the operation: slight swelling remains in the area of the right knee joint, there are no pathological changes in the scars, palpation is painless, and the range of motion is slightly limited. Follow-up examination 3 months after the operation: the patient reported no complaints, and the function of the

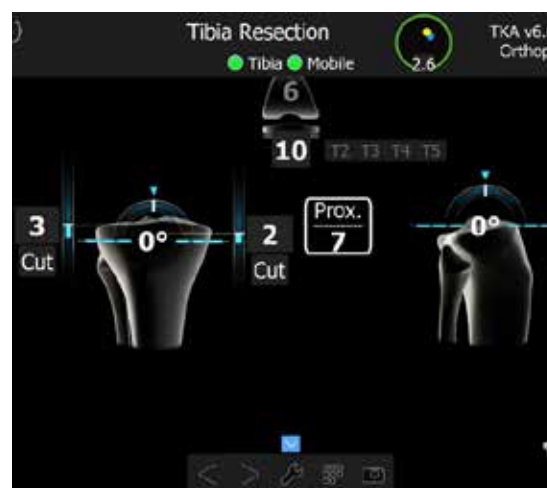


Fig. 2. Example: at a 0° tilt angle of the resection block, the resection height for the medial tibial condyle is 2 mm, and for the lateral tibial condyle – 3 mm

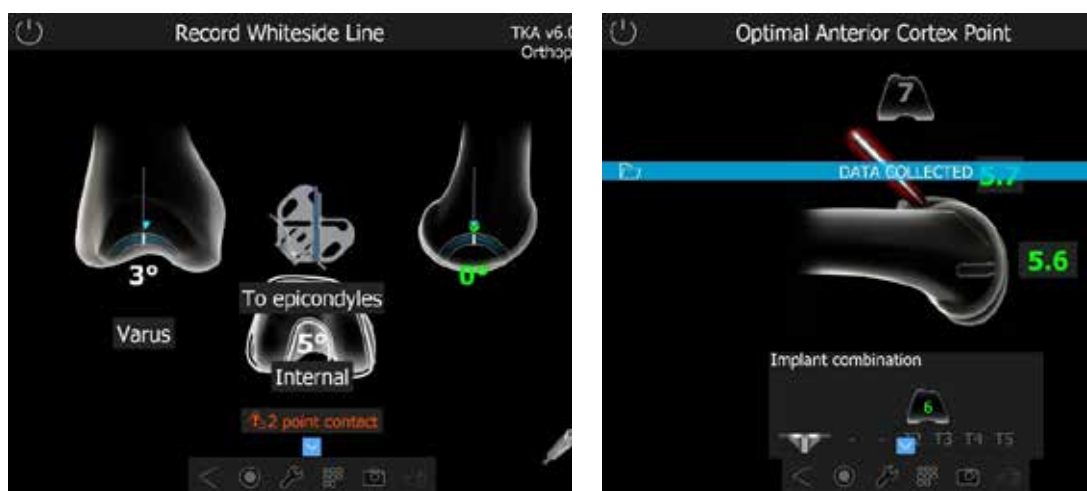

Fig. 3. Schematic image of points to determine the femoral component size

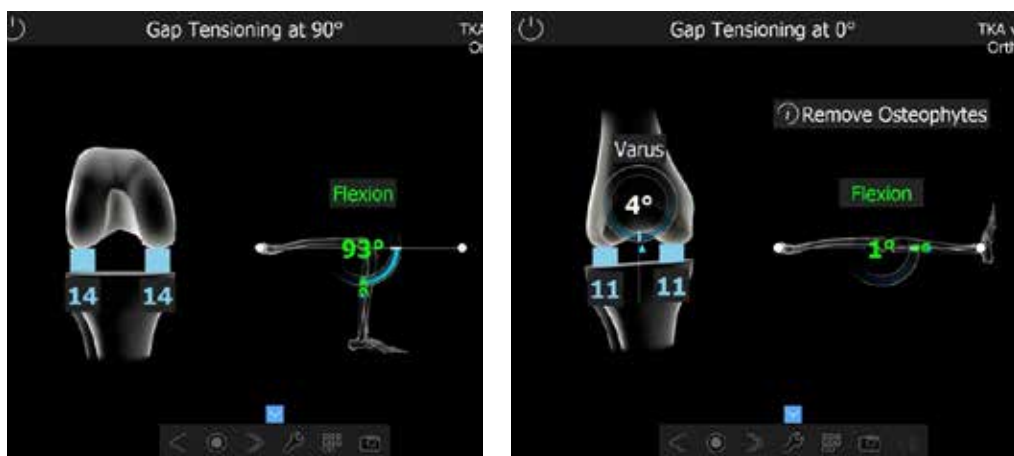

Fig. 4. Collateral ligament stress test (14 mm at 93° tibial flexion and 11 mm at 1° tibial flexion)

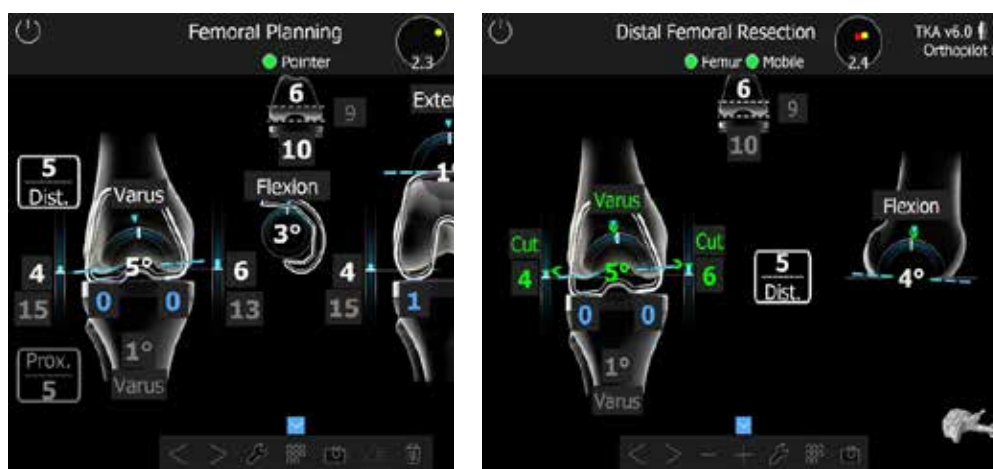

Fig. 5. Femoral planning stage, enabling selection of the most appropriate femoral component size and determination of the resection amount required for anatomically correct endoprosthesis implantation

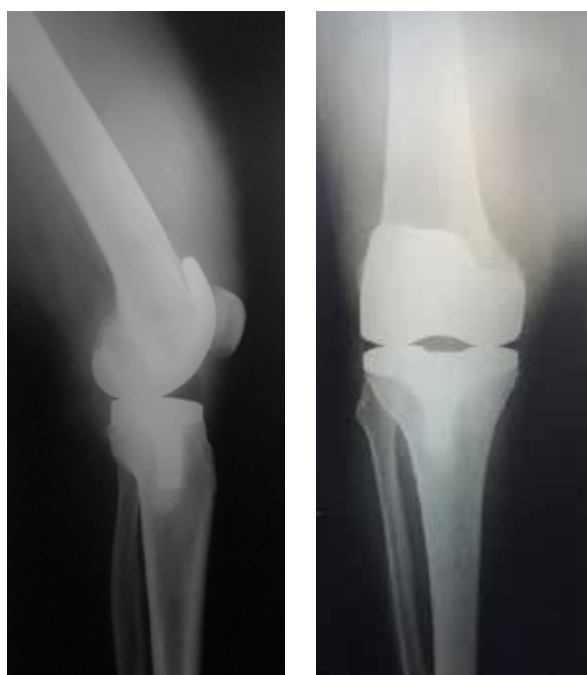

Fig. 6. Radiographs of Patient S., 55 years old, following primary total cemented right knee arthroplasty performed under computed navigation system control

operated knee joint was assessed as satisfactory, there was no edema, the patient moved without additional support, limping slightly on her right leg.

Blood loss and the duration of the rehabilitation period do not exceed the average when using traditional navigation systems, even despite the duration of the operation, which indicates the reliability and safety of the method.

Discussion

Among the various options of the newest navigation systems, which are divided into computerized and robotic. The computerized navigation systems are divided into large console navigation systems (with or without the need for pre-visualization) and manual accelerometer navigation systems [11]. The Orthopilot system is a large console navigation system without the need for pre-visualization. Taking into account the experience and scientific achievements of surgeons around the world, we can talk about the effectiveness of using a computerized navigation system in total knee arthroplasty, because the technique allows us to take care of more aspects than traditional navigation systems and to do it more precisely. The most promising area is difficult arthroplasty: revision or for patients with contraindications to the use of traditional mechanical navigation systems. It is too early to draw conclusions about the long-term prospects, especially in terms of the durability of the installed implants, but at the early postoperative stage there is no significant difference

between prostheses installed using mechanical navigation systems and computerized ones. Even despite the longer surgery duration when using a computerized navigation system, an increase in the number of complications is not observed [12], which allows us to characterize the navigation system that was used as a balanced tool in terms of accuracy among the various options of the latest navigation systems.

Conclusions

1. The computed navigation system for knee arthroplasty enables highly accurate implantation of endoprosthesis components in the correct position, ensuring optimal axial load distribution across the medial and lateral compartments.
2. The computed navigation system, prevents disruption of knee joint ligament balance, and minimises intraoperative blood loss (calculated ml/min – blood loss to surgery time). Correct placement of the endoprosthesis facilitates early initiation of painless rehabilitation, which in turn decreases the risk of complications such as joint contracture and persistent pain.
3. Comprehensive rehabilitation following knee arthroplasty is a crucial component of functional recovery and should commence early in the postoperative period.
4. The use of the computed navigation system ensures anatomically accurate positioning of prosthetic components and offers significant advantages over conventional navigation techniques in terms of convenience and accuracy of work, in our opinion.

BIBLIOGRAPHY

1. Kolesnichenko VA, Golka GG, Khanyk TY, Veklych VM. Epidemiology of knee osteoarthritis [Epidemiolohiya osteoartrozu kolinnoho suhloba]. *The Journal of V.N. Karazin Kharkiv National University, series "Medicine"*. 2021 Dec 1; 2021(43):115–26. DOI: 10.26565/2313-6693-2021-43-12 (in Ukrainian).
2. Osadchuk TI, Kalashnikov AV, Kostohryz OA, Protsenko VV. Surgical treatment of patients with osteoarthritis of the knee joints [Operatyvne likuvann`ya khvoryh na osteoartroz kolinnih suhlobiv]. *Clinical and preventive medicine*. 2023 Dec 24; 2023(7):13–20. DOI: 10.31612/2616-4868.7.2023.02 (in Ukrainian).
3. Gemayel AC, Varacallo MA. Total Knee Replacement Techniques. *Stat Pearls*. 2023 Aug 4; In: StatPearls. Treasure Island (FL): StatPearls Publishing; 2025 Jan. PMID: 30855796.
4. Varacallo MA, Luo TD, Mabrouk A, Johanson NA. Total Knee Arthroplasty Techniques. *StatPearls*. 2024 May 6; In: StatPearls. Treasure Island (FL): StatPearls Publishing; 2025 Jan. PMID: 29763071.
5. Zazirnyi IM, Ryzhkov B. The evolution of the total knee arthroplasty for the last 50 years [Rozvytok totalnoho endoprotezuвання kolinnoho suhloba za ostanni 50 rokiv]. *Trauma*. 2021 Nov 3;20(4):6–13. DOI: 10.22141/1608-1706.4.20.2019.178741 (in Ukrainian).
6. Canovas F, Dagneaux L. Quality of life after total knee arthroplasty. *Orthopaedics & Traumatology: Surgery & Research*. 2018 Feb 1;104(1):S41–6. DOI: 10.1016/J.OTSR.2017.04.017.
7. Osei DA, Rebehn KA, Boyer MI. Soft-tissue Defects after Total Knee Arthroplasty: Management and Reconstruction. *Journal of the American Academy of Orthopaedic Surgeons*. 2016 Nov 1;24(11):769–79. DOI: 10.5435/JAAOS-D-15-00241.
8. Alcelik IA, Blomfield MI, Diana G, et al. A Comparison of Short-Term Outcomes of Minimally Invasive Computer-Assisted vs Minimally Invasive Conventional Instrumentation for Primary Total Knee Arthroplasty. A Systematic Review and Meta-Analysis. *Journal of Arthroplasty*. 2016 Feb 1;31(2):410–8. DOI: 10.1016/j.arth.2015.09.013.
9. Miyasaka T, Kurosaka D, Saito M, Omori T, Ikeda R, Marumo K. Accuracy of Computed Tomography–Based Navigation-Assisted Total Knee Arthroplasty: Outlier Analysis. *Journal of Arthroplasty*. 2017 Jan 1;32(1):47–52. DOI: 10.1016/j.arth.2016.05.069.
10. Prasad N, Padmanabhan V, Mullaji A. Blood loss in total knee arthroplasty: an analysis of risk factors. *Int Orthop*. 2006 Feb;31(1):39. DOI: 10.1007/s00264-006-0096-9.
11. Shah SM. After 25 years of computer-navigated total knee arthroplasty, where do we stand today? *Arthroplasty*. 2021 Dec 1;3(1):1–8. DOI: 10.1186/s42836-021-00100-9.
12. Luan Y, Wang H, Zhang M, Li J, Zhang N, Liu B, et al. Comparison of navigation systems for total knee arthroplasty: A systematic review and meta-analysis. *Front Surg*. 2023 Jan 17;10:1112147. PMID: 36733891.

Надійшла до редакції 19.06.2025

Прийнята до друку 01.09.2025

Електронна адреса для листування yura.pavlychko@ukr.net