

UDC 616.45-022-089.819-089.87

DOI <https://doi.org/10.32782/2226-2008-2024-3-4>

R. S. Parfentiev <https://orcid.org/0000-0002-4058-7534>

V. V. Slepov <https://orcid.org/0000-0003-1581-5205>

SHORT-TERM AND LONG-TERM RESULTS OF TRANSPERITONEAL AND RETROPERITONEAL ENDOSCOPIC ADRENALECTOMY FOR HORMONE-ACTIVE TUMORS OF THE ADRENAL GLANDS

Odesa National Medical University, Odesa, Ukraine

UDC 616.45-022-089.819-089.87

R. S. Parfentiev, V. V. Slepov

SHORT-TERM AND LONG-TERM RESULTS OF TRANSPERITONEAL AND RETROPERITONEAL ENDOSCOPIC ADRENALECTOMY FOR HORMONE-ACTIVE TUMORS OF THE ADRENAL GLANDS

Odesa National Medical University, Odesa, Ukraine

The purpose of the present paper was to conduct a comparative study of the short-term and long-term results of transabdominal laparoscopic adrenalectomy (TLA) and retroperitoneal adrenalectomy (RPA) to develop clear indications for the use of optimal methods of endoscopic adrenalectomy.

Materials and methods. A retrospective analysis of the results of endoscopic adrenalectomy was conducted in 472 patients, including 282 with hormone-active tumors of the adrenal glands, operated in 2000–2021 at the Odesa Regional Hospital (Odesa, Ukraine). The mean age of the patients was (50.7 ± 0.6) years, with a predominance of women (65.2%).

The results. The duration of surgical intervention in TLA group was (83.1 ± 3.8) min, RPA group – (56.7 ± 4.9) min ($p < 0.05$). Blood loss in TLA group was (111 ± 7) ml, RPA group – (82 ± 9) ml ($p < 0.5$). The need for conversion occurred in 8 (4.9%) cases in TLA group and in 3 (2.5%) cases in RPA group ($p > 0.05$). Indicators of the quality of life in remote period after the operation were studied in 76 patients (43 of TLA group and 33 of RPA group). Our study proved that two years after the intervention the quality of life did not differ in patients of TLA and RPA groups (67.5 vs. 69.2 points).

Better results of quality of life in RPA group are achieved in patients with smaller hormone-active tumors ($r = -0.63$ $p < 0.05$). In TLA group, the dependence of quality of life on tumor size was lower ($r = -0.34$ $p < 0.05$).

Conclusions:

1. The complications rate after RPA is much lower than after TLA.
2. At the long-term period, the use of RPA is associated with a higher quality of life.
3. Retroperitoneal adrenalectomy should be recommended as the method of choice for the surgical treatment of small hormone-active adrenal tumors.

Keywords: adrenal tumors, surgical treatment, endoscopic interventions, retroperitoneal access, quality of life.

УДК 616.45-022-089.819-089.87

Р. С. Парфентьев, В. В. Слєпов

НАЙБЛИЖЧІ ТА ВІДДАЛЕНІ РЕЗУЛЬТАТИ ТРАНСПЕРИТОНЕАЛЬНОЇ ТА ЗАОЧЕРЕВИННОЇ ВІДЕОЕНДОСКОПІЧНОЇ АДРЕНАЛЕКТОМІЇ У РАЗІ ГОРМОНАЛЬНО АКТИВНИХ ПУХЛИН НАДНИРКОВИХ ЗАЛОЗ

Одеський національний медичний університет, Одеса, Україна

Метою цього дослідження було порівняння клінічної ефективності різних підходів до виконання відеоендоскопічної адrenaлектомії.

Проведено ретроспективний аналіз результатів лікування 472 пацієнтів з пухлинами надниркових залоз, оперованих у 2000–2021 рр. на базі Одеської обласної лікарні (м. Одеса, Україна). Показано, що частота ускладнень після ретроперитонеальної адrenaлектомії (РПА) значно нижча, ніж після трансабдоминальної лапароскопічної адrenaлектомії (ТЛА). На довгостроковому етапі використання РПА пов'язане з вищою якістю життя. ЗАОчеревинну адrenaлектомію слід рекомендувати як метод вибору для хірургічного лікування гормонально активних пухлин надниркових залоз невеликого розміру.

Ключові слова: пухлини наднирників, хірургічне лікування, відеоендоскопічні втручання, ретроперитонеальний доступ, якість життя.

© R. S. Parfentiev, V. V. Slepov, 2024

Стаття поширюється на умовах ліцензії



Adrenal tumours are rare [1–3]. With the use of modern medical imaging technologies, it has become known that the prevalence of adrenal tumours is 4–7% in people over 40 years of age, rising up to 5–10% at 70 years and older. The similar data were obtained in post-mortem studies. Most of these tumours do not manifest themselves clinically. However, from 3 to 30% of all the adrenal tumours are malignant, and 11–25% are hormone-active [1]. Conservative treatment of symptomatic adrenal tumours is ineffective [4].

Since the time of Knowsley–Thornton J., who first successfully performed adrenalectomy in 1889, scientific progress has significantly changed approaches to the surgical treatment of adrenal tumours. A laparoscopic removal of adrenal tumours has been recently developed, having significant advantages over laparotomy [5]. Approaches to surgical treatment changed dramatically in 1992, when a Canadian surgeon Gagner M. developed a laparoscopic technique for the removal of adrenal tumours. Much later, a Turkish surgeon Marcan S. and a German surgeon Waltz M. developed the retroperitoneal endoscopic adrenalectomy technique [6].

Despite ample literature data about the results of transabdominal laparoscopic adrenalectomy (TLA) [6–9] and retroperitoneal adrenalectomy (RPA) [10,11], it is not yet clear which method gives better results.

The aim of the present study was to investigate and compare short-term and long-term results of TLA and RPA in order to develop clear indications for the use of optimal methods of endoscopic adrenalectomy.

Materials and methods. retrospective analysis of the results of endoscopic adrenalectomy was conducted in 472 patients (including 282 with hormone-active adrenal tumours) who were operated at the Odesa Regional Hospital (Odesa, Ukraine) from January 2000 to December 2021. The structure of interventions in patients with hormone-active tumours is shown in Figure 1.

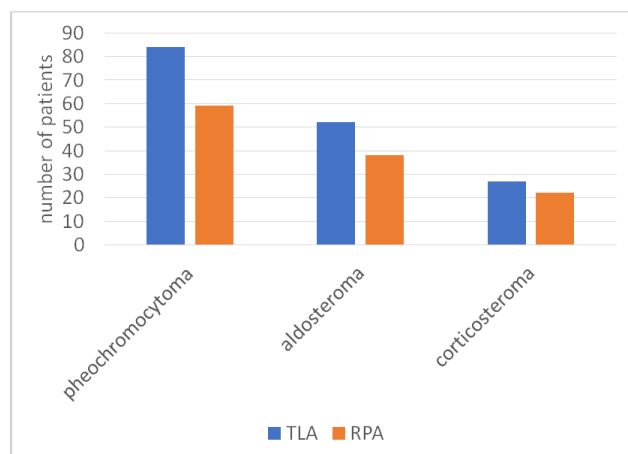


Fig. 1. Structure of surgical interventions for hormone-active adrenal tumours

The age of patients ranged from 19 to 79 years (mean age (50.7±0.6) years); women predominated – 184 (65.2%). The size of tumours in the largest diameter ranged from 1 to 10 cm.

In order to verify the diagnosis, ultrasound, spiral computed tomography (CT) of the abdominal cavity

and magnetic resonance imaging (MRI) were used [12]. Adrenal hormonal activity was assessed by urinary methoxycatecholamine excretion, salivary and blood cortisol levels, renin and aldosterone levels, dehydroepiandrosterone sulfate and blood electrolytes, results of dexamethasone stress tests, and ACTH levels.

Indications for unilateral adrenalectomy were hormone-active adrenal tumours up to 10 cm in diameter. The patients with pheochromocytoma received high doses of alpha-blockers (phenoxybenzamine 2–4 mg/kg orally) before surgery. Patients with aldosteronoma received oral potassium-sparing diuretics and potassium chloride before surgery [6].

Unilateral total adrenalectomy was performed by two experienced surgeons. The single combined anaesthesia protocol was used for all patients. TLA and RPA were performed according to the methods described in the literature [13, 14]. Duration of surgery, intraoperative blood loss, speed of transition to open surgery, intensity of postoperative pain, need for analgesics, episodes of nausea and vomiting, time to oral intake restoration, time to moving, length of hospital stay and postoperative complications (trocar hernia, need in hernioplasty) were recorded. The dynamics of blood pressure and the content of adrenal hormones in the blood and their metabolites in the urine were assessed. Postoperative complications were evaluated during hospitalisation and in 10–14 days, 1, 3, 12, 24, 36, 48 and 60 months after surgery.

The duration of the operation was measured from the moment of skin incision to surgical wound closure. Intraoperative blood loss was calculated on the basis of the saline hematocrit of the irrigation fluid in relation to the blood hematocrit.

Pain intensity was assessed using the visual analogue scale (VAS) [15] in 6, 12, and 24 hours after surgery.

In addition, patients’ quality of life was assessed using the SF-36 questionnaire [16]. For this purpose, special questionnaires were sent to patients 10–14 days before surgery and 1, 2, and 3 years after surgery, which were used to calculate quality of life indicators. The data obtained were interpreted by individual subscales and a total weighted score.

The study was conducted in compliance with the requirements of the Law of Ukraine “On Medicines” No. 123/96-VR of 04.04.96, Art. 8; Directive 2001/20/EC of the European Parliament and of the EC Council; Convention for the Protection of Human Rights and Dignity of the Human Being with regard to the Application of Biology and Medicine Convention on Human Rights and Biomedicine (1997), Section II “Consent”, Section V “Scientific Research” – Art. 15, 16, 17, the Declaration of Helsinki: Guidelines for Physicians for Biomedical Research Involving Human Subjects (1964); WHO recommendations; requirements of Good Clinical Practice (GCP); ethical and moral and legal aspects (clause 2.1.) of the Regulation on the Ethics Commission (Order of the Ministry of Health of Ukraine No. 66 of 13.02.2006). All the study participants were informed about the objectives, organisation, and methods of the study and signed an informed consent to participate in the study; all measures were taken to provide patient anonymity during the

study. The study protocol was approved at the meeting of the ONMedU Bioethics Committee (protocol 1a/N 12.02.2000).

The statistical significance of categorical variables was determined using the χ^2 criterion, and continuous variables were analysed using the Student's t-test. All statistical analyses were performed using Statistica 14.1.25 (TIBCO, USA) [17].

Results and discussion. All the surgical interventions were performed successfully. The duration of surgical intervention in TLA group was (83.1±3.8) min, RPA group – (56.7±4.9) min ($p < 0.05$). Blood loss in TLA group was (111±7) min, RPA group – (82±9) min ($p < 0.5$). The need for conversion was in 8 (4.9%) cases in TLA group and in 3 (2.5%) cases in RPA group ($p > 0.05$).

All patients experienced pain in the postoperative period. In 6 hours, the pain intensity was (5.3±0.3) points by VAS scale in TLA group and (2.6±0.2) points in RPA group. In 12 hours, the pain intensity was (4.9±0.2) points in TLA group and (2.3±0.1) points in RPA group, and in 24 hours – (3.9±0.2) and (1.9±0.2) points, respectively. In some patients, nausea (28.2% vs. 19.3%) and vomiting (16.0% vs. 5.0%) were observed at the postoperative period.

Among 282 patients with hormone-active tumours, complete normalisation of blood pressure (BP) occurred in 36(25.2%)patients with pheochromocytoma. Normalisation of BP did not take place in 19 (21.1%) patients with aldosteroma and 9 (18.4%) patients with corticosteroma; they continued therapy with antihypertensive drugs. So, the unilateral adrenalectomy did not help to normalise BP in 22.7% of patients with hormone-active tumours.

Of 163 patients who underwent TLA, trocar hernias were observed in 15 (9.2%). Repeated operations for trocar hernias were performed in 13 patients, in 7 cases by a laparoscopic approach, in 6 patients by an open approach. 2 patients refused from surgical treatment of trocar hernias because of advanced age, the bandages were used to prevent hernia strangulation.

Of 39 patients who underwent transabdominal surgical interventions after TLA, symptoms of adhesive disease with partial intestinal obstruction were observed in 8 (20.5%); 6 of them were performed repeated operations for adhesive intestinal obstruction, 2 – laparoscopic operations, 4 patients had open laparotomy. Hernia formation was not observed in 156 patients who underwent retroperitoneal laparoscopic adrenalectomy. Despite the fact that 34 (21.8%) patients underwent abdominal interventions before RPA, no symptoms of adhesion with clinical signs of partial intestinal obstruction were detected in any case. So, RPA has advantages over TLA in the absence of postoperative hernia formation and adhesive disease with elements of intestinal obstruction.

In 76 patients (43 of TLA group and 33 of RPA group), we studied the quality of life in remote period after surgery. As our studies have shown (Fig. 2), in two years after the intervention, the quality of life did not differ in patients of TLA and RPA groups (67.5 vs. 69.2 points).

At the same time, the quality-of-life indicators of patients with hormone-active tumours were slightly lower than those with inactive tumours (68.2 vs. 47.4 points, $p < 0.05$). In 3 years, the quality-of-life indicators improved in both groups of patients and did not differ significantly in the TLA and

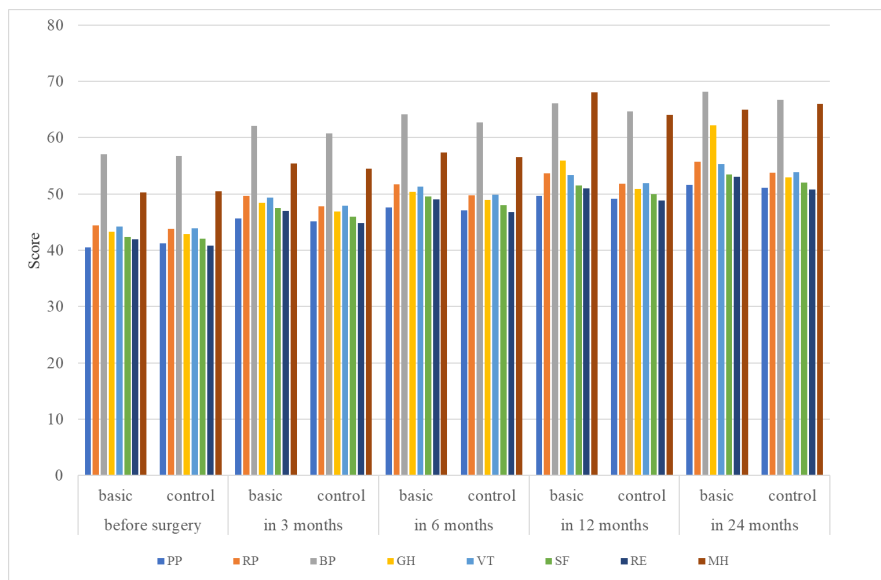


Fig. 2. Quality of life of patients before and after adrenalectomy:

- PP – physical performance
- RP – physical role functioning
- BP – body pain
- GH – general health perception
- VT – vitality
- SF – social functioning
- RE – emotional role functioning
- MH – mental health

RPA groups (80.3 vs. 85.4 points, $p < 0.05$). The quality-of-life indicators increased significantly in patients with hormone-active tumours as compared to the preoperative level than in patients with hormone-inactive tumours.

Further analysis showed that the best quality of life indicators in RPA group were achieved in patients with smaller hormone-active tumours ($r = -0.63$, $p < 0.05$). In TLA group, the dependence of quality of life on tumour size was less ($r = -0.34$, $p < 0.05$).

These results are compliant to observations of other authors to certain extent. For example, Prudhomme T et al. (2021) state that both transabdominal and retroperitoneal approaches for endoscopic adrenalectomy are safe, with equivalent rates of serious complications and mortality. The surgical conversion rate is higher for the transperitoneal approach. The authors believe that the retroperitoneal approach should be used for small adrenal lesions [10].

In the other work, RPA was shown to be a safe procedure and provide satisfactory results. The method offers the additional benefits of direct surgical access, opportunities for patients with previous abdominal surgery, a high body mass index and several comorbidities. The authors consider the possibility of intensive training of surgeons in this promising method [11].

Conclusions:

1. The incidence of complications after retroperitoneal adrenalectomy is significantly lower than after transabdominal laparoscopic adrenalectomy.

2. In the remote period, the use of retroperitoneal adrenalectomy is associated with a higher quality of life.

3. Retroperitoneal adrenalectomy should be recommended as a method of choice for the surgical treatment of small hormone-active adrenal tumours.

The authors declare no conflict of interests.

BIBLIOGRAPHY

1. Ebbehøj A, Li D, Kaur RJ, et al. Epidemiology of adrenal tumours in Olmsted County, Minnesota, USA: a population-based cohort study. *Lancet Diabetes Endocrinol.* 2020; 8 (11): 894–902. doi:10.1016/S2213-8587(20)30314-4.
2. Jing Y, Hu J, Luo R, et al. Prevalence and Characteristics of Adrenal Tumors in an Unselected Screening Population. A Cross-Sectional Study. *Ann Intern Med.* 2022; 175 (10): 1383–1391. doi: 10.7326/M22-1619.
3. Duh Quan-Yang. Understanding the epidemiology of adrenal tumours. *The Lancet Diabetes & Endocrinology.* 2020; 8 (11): 871–873. doi: 10.1016/S2213-8587(20)30335-1.
4. Lee JM, Kim MK, Ko SH, et al. Clinical Guidelines for the Management of Adrenal Incidentaloma. *Endocrinol Metab.* 2017; 32 (2): 200–218. doi: 10.3803/EnM.2017.32.2.200.
5. Harris D., Wheeler M. History of Adrenal Surgery <http://eknygos.lsmuni.lt/springer/10/0%201-6.pdf>.
6. Grubnik VV, Parfentiev RS, Grubnyk VV, Grubnik YV, Sliepov VV. Transabdominal and retroperitoneal adrenalectomy: comparative study. *Surg Endosc.* 2024; 38 (3): 1541–1547. doi: 10.1007/s00464-023-10533-9.
7. Raffaelli M, De Crea C, Bellantone R. Laparoscopic adrenalectomy. *Gland Surg.* 2019; 8 (1): 41–52. doi: 10.21037/gs.2019.06.07.
8. Isiktas G, Akgun E, Berber E. Laparoscopic versus robotic lateral transabdominal adrenalectomy. *J Surg Oncol.* 2024; 129 (2): 224–227. doi: 10.1002/jso.27493.
9. Uludağ M, Aygün N, İsgör A. Surgical Indications and Techniques for Adrenalectomy. *Sisli Etfal Hastan Tip Bul.* 2020; 54 (1): 8–22. doi: 10.14744/SEMB.2019.05578.
10. Prudhomme T, Roumiguié M, Gas J, Soulié M, Thoulouzan M, Huyghe E. Comparison between retroperitoneal and transperitoneal laparoscopic adrenalectomy: Are both equally safe? *J Visc Surg.* 2021; 158 (3): 204–210. doi: 10.1016/j.jvisc.2020.07.009.
11. Lee SYH, Wong C. Time to Flip the Approach: Retroperitoneoscopic Adrenalectomy. *J Surg Res.* 2024; 296: 189–195. doi: 10.1016/j.jss.2023.12.032.
12. Corssmit EPM, Dekkers OM. Screening in adrenal tumors. *Curr Opin Oncol.* 2019; 31 (3): 243–246. doi: 10.1097/CCO.0000000000000528.
13. Matsuda T, Murota T, Kawakita M. Transperitoneal anterior laparoscopic adrenalectomy: the easiest technique. *Biomed Pharmacother.* 2000; 54 (1): 157–160. doi: 10.1016/s0753-3322(00)80034-7.
14. Munver R, Ilbeigi P. Retroperitoneal laparoscopic adrenalectomy. *Curr Urol Rep.* 2005; 6 (1): 72–7. doi: 10.1007/s11934-005-0070-x.
15. Reed MD, Van Nostran W. Assessing pain intensity with the visual analog scale: a plea for uniformity. *J Clin Pharmacol.* 2014; 54 (3): 241–4. doi: 10.1002/jcph.250.
16. Lins L, Carvalho FM. SF-36 total score as a single measure of health-related quality of life: Scoping review. *SAGE Open Med.* 2016; 4: 2050312116671725. doi: 10.1177/2050312116671725.
17. Fetisov VS. Paket statystychnoho analizu danykh STATISTICA: navch. posib. *Nizhyn, NDU im. M. Hoholia*, 2018; 114. (in Ukrainian).

Надійшла до редакції 03.05.2024.

Прийнята до друку 30.08.2024.

Електронна адреса для листування roman.parfentiev@onmedu.edu.ua