

UDC 617.52-089.844-048.78

DOI <https://doi.org/10.32782/2226-2008-2023-4-16>

*D. L. Feinendegen*<sup>1,2</sup> <https://orcid.org/0000-0002-8508-5036>

*S. Y. Feinendegen*<sup>3</sup>

*V. V. Grubnik*<sup>2</sup> <https://orcid.org/0000-0003-4389-908X>

## VERSATILITY AND REFINEMENTS OF V/Y PERFORATOR FLAPS FOR FACIAL RECONSTRUCTION

<sup>1</sup>Institute Feinendegen of Plastic, Reconstructive and Aesthetic Surgery, Zurich, Switzerland

<sup>2</sup>Odesa National Medical University, Odesa, Ukraine

<sup>3</sup>Institute of Ethics, History and Theory of Medicine, LMU Munich, Munich, Germany

UDC 617.52-089.844-048.78

*D. L. Feinendegen*<sup>1,2</sup>, *S. Y. Feinendegen*<sup>3</sup>, *V. V. Grubnik*<sup>2</sup>

### VERSATILITY AND REFINEMENTS OF V/Y PERFORATOR FLAPS FOR FACIAL RECONSTRUCTION

<sup>1</sup>*Institute Feinendegen of Plastic, Reconstructive and Aesthetic Surgery, Zurich, Switzerland*

<sup>2</sup>*Odesa National Medical University, Odesa, Ukraine*

<sup>3</sup>*Institute of Ethics, History and Theory of Medicine, LMU Munich, Munich, Germany*

**Background.** Y perforator flaps for facial reconstruction have gained great popularity in the last years. The advantages compared to randomized local flaps are the marked increased arc of rotation and transfer length as well as less lymphatic congestion. The paper aims to show the field of application in facial reconstruction and has the purpose to serve as a continuing education.

**Methods.** With 6 clinical case presentations the versatility and some refinements of V/Y perforator flaps for facial reconstruction are presented. The general principle of the operative procedure is explained in detail.

**Results.** Beside the well-known treatment options for the different facial areas with different perforator containing layers a novel myocutaneous forehead flap is introduced for reconstruction of a supraorbital defect.

**Conclusion.** During the last years, V/Y perforator flaps have become an important tool for functional and aesthetical sufficient facial reconstruction. And it has proven its right of existence in facial plastic surgery.

**Key words:** facial reconstruction, facial blood supply, V/Y flap, perforator flaps.

УДК 617.52-089.844-048.78

*Д. Л. Фінендеген*<sup>1,2</sup>, *С. І. Фінендеген*<sup>3</sup>, *В. В. Грубнік*<sup>2</sup>

### Універсальність та вдосконаленість перфораційних V/Y клаптів для реконструкції обличчя

<sup>1</sup>*Інститут пластичної, реконструктивної та естетичної хірургії Фінендеген, Цюріх, Швейцарія*

<sup>2</sup>*Одеський національний медичний університет, Одеса, Україна*

<sup>3</sup>*Інститут етики, історії та теорії медицини, Мюнхенський університет Людвіга-Максиміліана, Мюнхен, Німеччина*

**Довідка.** В останні роки великої популярності набули V/Y перфораційні клапті для реконструкції обличчя. В порівнянні з рандомізованими локальними клаптями, їх перевагами є помітно збільшена дуга обертання і довжина перенесення, а також менший лімфатичний застої. Ціль статті показати область застосування відповідних клаптів у реконструкції обличчя та зробити внесок у царину безперервної освіти.

**Методи.** На прикладі 6 клінічних випадків показано універсальність і вдосконаленість V/Y перфораційних клаптів для реконструкції обличчя. Детально пояснюється загальний принцип оперативного втручання.

**Результати.** Окрім розповсюджених видів терапії ділянок обличчя з використання різних перфораційних клаптів, для реконструкції супраорбітального дефекту впроваджено новий м'язово-шкірний лобний клапоть.

**Висновки.** Останнім часом V/Y перфораційні клапті стали важливим інструментом для функціональної та естетичної реконструкції обличчя та довели своє право на існування в пластичній хірургії обличчя.

**Ключові слова:** реконструкція обличчя, лицева артерія, V/Y клапті, перфораційні клапті.

### Introduction

Soft tissue defects along the face after tumor resection, trauma or infection, which cannot be closed primarily, are always a challenge for the reconstructive surgeon. For satisfying aesthetic and functional results, it is necessary to use surrounding skin with similar semblance, which precisely restores and imitates missing parts with its contour.

There is a great variety of local flaps in the armamentarium to treat such defects, like transposition flaps, bilobed flaps,

rotation flaps or distant flaps like the forehead flap [1–4]. In recent years, “perforator flaps” have gained popularity. Because of the dense vascularity in the face perforator flaps are very useful tools for aesthetical and functional sufficient soft tissue reconstruction in the face. They have been widely accepted and proven to have significant advantages compared to local flaps with random vascularization [5–17].

Perforators are the vessels originating from branches of axially running arteries arising from the depth and perforating the underlying fascia and/or muscle and finally reaching the subcutaneous layer and skin (Fig. 1).

All areas of skin are more or less nourished by perforator vessels and can be found adjacent to the defect.

© D. L. Feinendegen, S. Y. Feinendegen, V. V. Grubnik, 2023

Стаття поширюється на умовах ліцензії



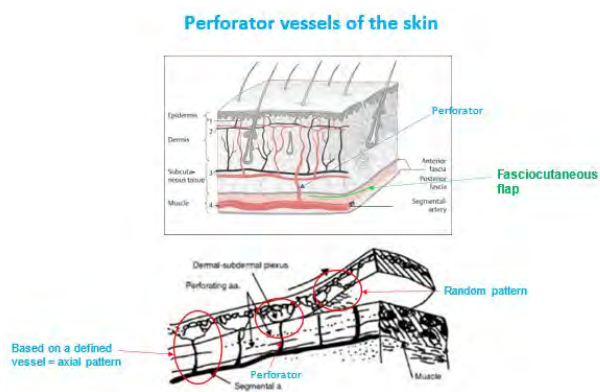


Fig. 1.

The schematic drawings demonstrate the vessels distribution with the perforators arising from the muscles climbing up into the skin layers. As an example, the dissecting layer of the “fasciocutaneous” perforator flap is marked (green line)

Because of the dense vascularity in all fascial tissue layers one can assume that even in a pure subcutaneous or fasciocutaneous pedicle of several centimeter length that more or less perforators are included guaranteeing the flap survival. Quite often one can see them during dissection shimmering through.

When planning such a way of reconstruction the surgeon must be able to close the secondary defect which will emerge after transfer of the perforator flap. Thus, one has to plan the whole procedure in kind of a two-tiered approach. Adjacent to the area from where the perforator flap originates, sufficient movable skin must be available to be able to close the secondary defect (Fig. 2).

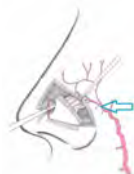

Fig. 2.

After dissection of the myo-fascial pedicle containing the perforator vessels (lateral branches of the nasal artery) the V/Y alar perforator flap can be shifted cranially (red arrow) to cover the defect along the lateral nasal tip. The secondary defect is closed by advancement of the neighboring skin (blue arrow)

Having been introduced by Blasius in 1848, the V/Y flap has gained popularity in closing soft tissue defects at all parts of the body by sliding a subcutaneous random pattern flap from tissue adjacent to the defect [18, 19]. The advantage of this technique is that color and texture perfectly match because adjacent soft tissue is used. Another advantage of this design is the ability to close the secondary defect primarily. A disadvantage is the very limited arc of rotation and mobility depending on the laxity of the underlying subcutaneous tissue. But by dissecting the pedicle nourishing the body of the V from one of its lateral edges, the arc of rotation can be maximally increased. Depending on the required arc of rotation more or less centimeters of pedicle length can be dissected to enable the sufficient reconstruction. This has been presented by Niranjani et al [5] and Yildirim et al. [8] who could show a wide arc of rotation and mobility of V/Y for the repair of defects in different areas of the body.

**Methods**

With 6 clinical case presentations the versatility and some refinements of V/Y perforator flaps for facial reconstruction are presented. 5 patients suffered from basal cell carcinomas and 1 patient from a squamous cell carcinoma. The medical data from all patients are shown in table 1. All patients have been operated and followed up by the main author (Fig. 3–9).

**Operative technique**

After carefully cleansing and disinfection of the whole facial skin the tumor margin and the design of the perforator flap, adjacent to the resulting defect, is drawn considering the aesthetical units and the skin tension lines. The main body of the flap is marked like a “V” and after flap transfer and inlay it looks like a “Y”. Therefore, it is called V/Y flap. The top of the V-body lies adjacent to the defect. The pedicle of the flap, arising from one of the lateral edges of the V is also marked. The required length of the pedicle to reach the defect area should be estimated carefully. As an example, figure 2 presents the planning of the V/Y alar perforator flap for nasal reconstruction (Fig. 2).

The skin margins of the flap are incised. The part which is located at the edge of the underlying pedicle is just cut to the subdermal layer and not deeper! The opposite side is cut down to the tissue of the perforator containing layer PCL (including the vessels and lymphatics). In the cheeks the PCL is the SMAS (superficial musculoaponeurotic system; fasciocutaneous flap), (Fig. 6–8), along the nose it is the myofascial layer (myofasciocutaneous flap), (Figures 3–5) and along the forehead it is the forehead

Table 1

**Medical data of the patients**

Patient	1: Fig 4	2: Fig 5	3: Fig 6	4: Fig 7	5: Fig 8	6: Fig 9
Gender/Age	Female/73	Male/83	Male/72	Male/79	Male/78	Male/84
Kind of tumour	BCC	BCC	BCC	BCC	BCC	SCC
Location of tumour	Upper alar of the nose	Nasal tip	Lower half of the alar of the nose	Ear lobe	Cheek	forehead
Medical risk factors	none	High RR, smoker, ASS 100	Smoker	Diabetes Mellitus Typ 1	High RR, thyroid hypofunction	Former radiotherapy of the right temporal area; high RR, blood thinning c Marcoumar

Abbreviations: BCC = basal cell carcinoma; SCC = squamous cell carcinoma; RR = blood pressure; Ass 100 = Aspirin cardio; c = with

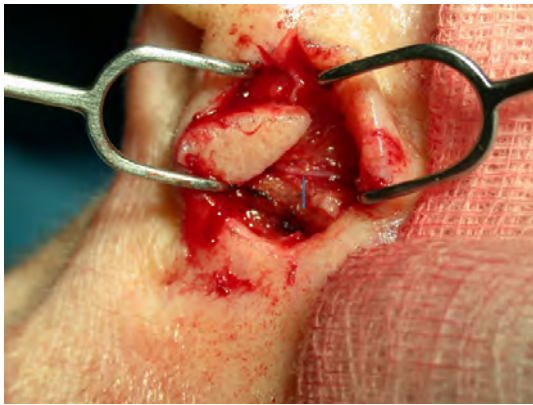

Fig. 3.

A V/Y alar perforator flap for reconstruction of the alar of the nose. The blue arrow marks one of the perforator vessels

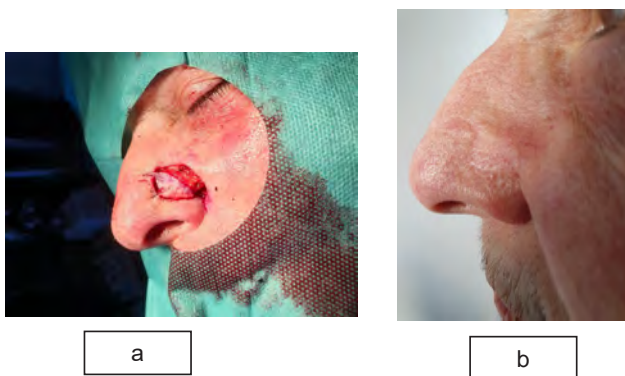

Fig. 4 A/B.

Figure 4 presents the reconstruction of the left alar of the nose with a V/Y alar perforator flap in a 73-year-old female after resection of a basal cell carcinoma. The inset of a V/Y alar perforator flap. Both of the tips of the V are integrated into the suture line to “break off” the final scar (Figure 4 A) and therefore improve the final scar as is shown in figure 4 B

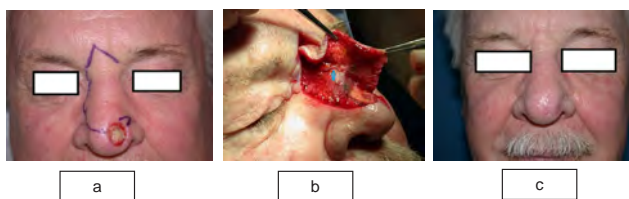


Fig. 5 A-C.

Figure 5 A shows the planning of the nasal tip reconstruction with a combination of a V/Y and rotation myofasciocutaneous perforator flap after removal of a basal cell carcinoma in a 83-year-old patient. After flap dissection the flap is rotated into the defect. In figure 5 B the perforator vessel is marked with a blue arrow. Figure 5 C presents the final outcome 6 months later with preservation of the nasal symmetry

muscle (musculocutaneous flap), (Fig. 9). The PCL along the opposite side is cut to the next facial layer which is at the cheek the fascia of the mimic muscles/parotid

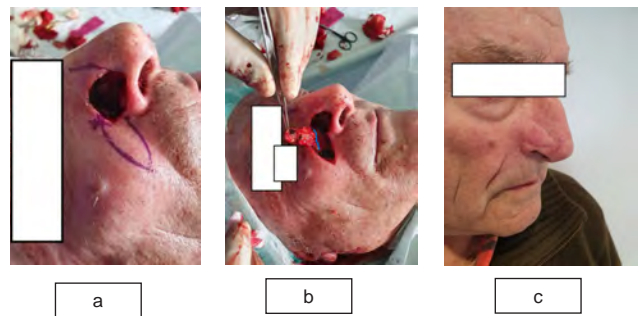


Fig. 6 A-C.

72 years old male with a big defect along the right ala of the nose after removal of a basal cell carcinoma (Figure 6 A). Reconstruction with a fasciocutaneous V/Y flap (based on the adjacent SMAS) from the right nasolabial fold. The blue line indicates the basis of the pedicle (Figure 6 B). The flap is shifted 180° into the ala of the nose. Figure 6 C presents the final result 6 months postop

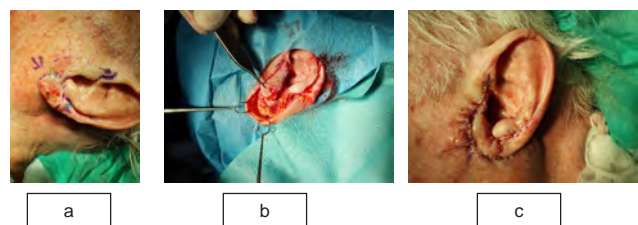


Fig. 7 A-C.

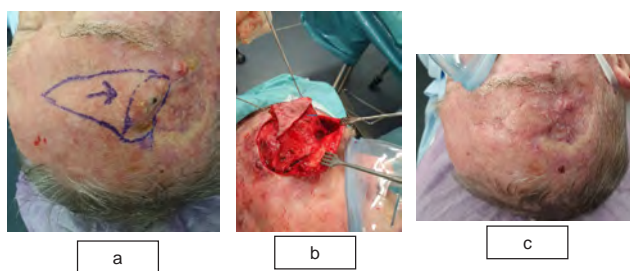
Figure 7 A presents a basal cell carcinoma involving the whole left earlobe from a 79-year-old male. A fasciocutaneous V/Y flap from preauricular (based on the adjacent SMAS, green arrow marks the shift of the flap) is combined with an advancement flap from the lower helical rim to close the resulting defect (green arrow and the red lines indicate the course of the perforator vessels which run inside the SMAS). In figure 7 B the flaps have been dissected and figure 7 C presents the final suture lines

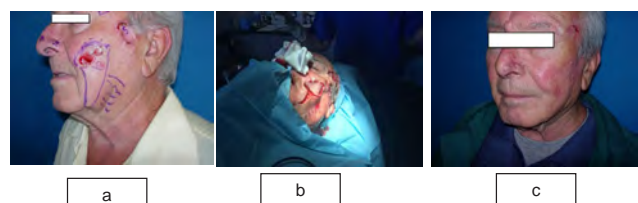

Fig. 8.

In figure 8 A a 78-year-old male is shown with an extensive recurrency of a basal cell carcinoma at the left cheek. Marking of the fasciocutaneous V/Y perforator flap (the nourishing vessels which run inside the SMAS, blue lines). After flap dissection and transfer (Figure 8 B) and the final result 5 months later (Figure 8 C)

fascia; along the nose the perichondrium or periosteum and along the forehead the periosteum. Dissection is then performed strictly in the subdermal layer to free the outer



**Fig. 9.**

**A 84-year-old patient with an extensive squamous cell carcinoma at the right supraorbital region. The right temporal area had been treated before with radiotherapy and therefore was not available for flap planning (Figure 9 A). A V/Y musculocutaneous flap (perforators run inside the frontal muscle) from the right forehead is the choice of treatment. The frontal muscle has been freed over the orbital crest saving the supraorbital neurovascular bundle, blue arrow indicates the supraorbital artery (Figure 9 B). Figure 9 C presents the final result 6 months later**

After complete dissection of the pedicle, the body of the V can be shifted up to 90° (Figure 6) or even more, without tension towards and into the adjacent defect. Wound closure is done by some single knot subcuticular sutures Biosyn 5-0 and then single knot and/or running final intracutaneous or cutaneous sutures Prolene 6-0. For better scar development the two peaks of the V are integrated into the wound closure to “break up” the concomitant scar and therefore improving its final quality (Fig. 4 A, B)

Dressing is applied with Fusidic acid/Betamethasone cream (Fucicort Cream, Leo Pharma, GmbH, Germany), a combination of antibiotic and a corticosteroid applied with a cotton wool plaster. The cutaneous stitches are removed one week postop, the suture lines are covered by adhesive strips (Steri-Strips®, 3M, MN, USA) for another week.

All patients were followed-up by the surgeon the first day and the first week, the third and the sixth week and then the third and the sixth month or later after surgery. The patients were instructed to use a sun blocker for the operated skin continuously over 6 months and if some lymphatic congestion might appear to frequently apply pressure during the first 3 weeks after the operation.

#### Discussion

In the 1990s perforator flaps were introduced which represented a further advancement in flap surgery. These flaps are supplied by small vessels (previously thought too small to sustain a flap) that typically arise from a named blood supply and penetrate muscle, muscle septum, or both to supply the overlying tissue (Fig. 1).

The perforators run either in the layer of the SMAS (cheeks), myo-fascial layer (nose) or inside the muscles of the face (forehead). Due to the extremely dense vascularity along the soft tissue layers of the face a multitude of perforator vessels nourishing the overlying skin can be found.

The facial skin is mainly vascularised by 3 branches of the external carotid artery: the facial artery (FA), the superficial temporal artery (STA) and the transverse facial artery (TFA) which is a branch of the STA [20, 21].

The concept of angiosomes of the head and neck have been well illustrated by Manchot in 1889 [23], Salmon in

1936 [24] and Cormack and Lamberty in 1986 [25]. Further important anatomical studies with insights for clinical applications also have been published [26, 29]. One of the main findings is that variations of the facial artery as well as variations of the arterial skin territories in the face are rare. As has been already proven by Salmon the FA vascularizes the inferior third of the nose, the lips and the chin, the STA supplies the temporal area, and a part of the frontal area, TFA nourishes the cheek, and the ophthalmic artery vascularizes the median part of the frontal area, the lids, and the upper two-thirds of the nose. These findings might be an important information for example in reconstructive cases and flap planning where former radiotherapy might have diminished blood supply in the correspondent area.

After Blasius 1948 has introduced the concept of the V/Y flap based on a random vascularization along a subcutaneous pedicle it gained great popularity. A big advantage of this technique is the ability to restore lost skin with tissue from the direct neighborhood resembling the same characteristics and qualities. When planning a V/Y perforator flap the surgeon must focus its attention on the flap location, considering the skin tension lines and the availability of sufficient amount of movable skin along the lower part of the V to close the secondary defect by simple skin advancement. This means another big advantage.

But a big disadvantage of the V/Y flap simple based on a random vascularized subcutaneous pedicle was the diminished arc of rotation and just little length for flap transposition. With incorporation of an axial pattern vascularity into the body of the V by dissection of adjacent local tissue including more or less perforator vessels, first described by Nirjanjan 2000 and Yildirim 2007, the arc of rotation and the transfer distance could be increased considerably [5, 8]

Another advantage of perforator flaps is the reduced risk of postoperative lymphedema like it is quite often the case with local random flaps. Especially when they have been dissected with small subcutaneous pedicles like in bilobed flaps or in small-based transposition flaps. They all bear the risk of developing long lasting lymphedema. The explanation for this phenomenon lies in the fact that the lymph drainage might be congested by small pedicles.

This complication to occur is much less in perforator flaps. This is due to the arrangement of the lymphatic vessels which run parallel to the perforators. It is therefore quite mandatory to dissect the pedicle with a sufficient cuff of soft tissue around the perforators to ensure the lymph drainage. As in fig. 3, 5 B, 6 B, 8 B, 9 B is demonstrated all the dissected pedicles measured at least several centimeters in diameter. Fig. 9 A–9 C present a novel technique, herein firstly described, by using a wide musculocutaneous pedicle including the perforator vessels for excellent supraorbital functional and aesthetical reconstruction. The flap design with axial blood and lymph flow optimizes the aesthetic result and guarantees flap survival without prolonged lymphatic or venous congestion.

#### Conclusion

During the last years, V/Y perforator flaps have become an important tool for functional and aesthetical sufficient facial reconstruction. And it has proven its right of existence in facial plastic surgery. The musculocutaneous perforator forehead flap for supraorbital reconstruction is presented for the first time here.

**BIBLIOGRAPHY**

1. Chu EA, Byrne PJ. Local flaps I: bilobed, rhombic, and cervicofacial. *Facial Plast Surg Clin North Am* 2009; 17: 349–60.
2. Kruter L, Rohrer T. Advancement Flaps. *Dermatol Surg*. 2015 Oct; 41 Suppl 10: 239–46. DOI: 10.1097/DSS.0000000000000497.
3. Yenidunya MO, Demirseren ME, Ceran C. Bilobed flap reconstruction in infraorbital skin defects. *Plast Reconstr Surg*. 2007 Jan; 119(1): 145–150.
4. Feinendegen DL, Langer M, Gault D: A combined V/Y-advancement and turnover flap for simultaneous perialar and alar reconstruction. *British Journal of Plastic and Reconstructive Surgery* 53: 248–250, 2000.
5. Niranjana NS, Price RD, Govilkar P. Fascial feeder and perforator-based V-Y advancement flaps in the reconstruction of lower limb defects. *Br J Plast Surg*. 2000; 53: 679–689.
6. Pepper JP, Baker SR. Local flaps: cheek and lip reconstruction. *JAMA Facial Plast Surg*. 2013 Sep-Oct; 15(5): 374–82.
7. Feinendegen DL, Langer MF, Roldán JC. Refinement of nasal reconstruction with a V/Y-alar-perforator flap. *Plast Reconstr Surg – Global Open*. 2017 Jan 30; 5(1): 1195.
8. Yildirim S, Taylan G, Aköz T. Freestyle perforator-based V-Y advancement flap for reconstruction of soft tissue defects at various anatomic regions. *Ann Plast Surg*. 2007; 58: 501–506.
9. Tae Ho Yoon, In Sik Yun, Dong Kyun Rha, Won Jai Lee. Reconstruction of Various Perinasal Defects Using Facial Artery Perforator-Based Nasolabial Island Flaps. *Arch Plast Surg* 2013; 40: 754–760.
10. Kardisag S, Ozcan A, Sumer O, Ugurlu K. Single-stage ala nasi reconstruction: lateral nasal artery perforator flap. *J Craniofac Surg* 2010; 21: 1887–9.
11. Ruiz-Moya A, Lagares-Borrego A, Infante-Cossio P. Propeller facial artery perforator flap as first reconstructive option for nasolabial and perinasal complex defects. *J Plast Reconstr Aesthet Surg* 2015; 68: 457–63.
12. Kannan RY, Mathur BS. Perforator flaps of the facial artery angiosome. *J Plast Reconstr Aesthet Surg* 2013; 66: 483–488.
13. Qassem Q, Havet E, Sinna R. Vascular basis of the facial artery perforator flap: analysis of 101 perforator territories. *Plast Reconstr Surg* 2012; 129: 421–9.
14. Madorsky S, Do A, Meltzer O. Superior Extended Nasal Myocutaneous Island Flap: An Alternative to Forehead Flap Reconstruction of the Nose. *Facial Plast Surg Aesthet Med*. 2020 Jul/Aug; 22(4): 294–300.
15. D'Arpa S, Cordova A, Pirello R, Moschella F. Free style facial artery perforator flap for one stage reconstruction of the nasal ala. *J Plast Reconstr Aesthet Surg* 2009; 62: 36–42.
16. Demirseren ME, Afandiyev K, Ceran C. Reconstruction of the perioral and perinasal defects with facial artery perforator flaps. *J Plast Reconstr Aesthet Surg* 2009; 62: 1616–20.
17. Hofer SO, Posch NA, Smit X. The facial artery perforator flap for reconstruction of perioral defects. *Plast Reconstr Surg* 2005; 115: 996–1003.
18. Blasius E. Operation von Narben. In: Blasius E, ed. Beiträge zur praktischen Chirurgie nebst einem Bericht über die chirurgisch-äugenärztliche Klinik der Königlichen Universität zu Halle. Berlin: Verlag von A. Förstner; 1848: 238.
19. Hauben DJ. Ernst Blasius's contributions to plastic surgery. *Plast Reconstr Surg*. 1984 Oct; 74(4): 561–70.
20. Niranjana NS. An anatomical study of the facial artery. *Ann Plast Surg* 1988; 21: 14–22.
21. Lohn JW, Penn JW, Norton J, Butler PE. The course and variation of the facial artery and vein: implications for facial transplantation and facial surgery. *Ann Plast Surg* 2011; 67: 184–8.
22. Lengelé B. Le visage, le masque et le temps. Histoire naturelle de l'architecture segmentaire de la face. *Bull Mem Acad R Med Belg* 2001; 156: 377–89.
23. Manchot C. The cutaneous arteries of the human body. New York: Springer Science Business Media; 1983. Cormack GC, Lamberty RGH. The arterial anatomy of skin flaps. Edinburgh: Churchill Livingstone; 1986.
24. Salmon M. Artères de la peau. Paris: Masson et Cie; 1936. 104–116.
25. Cormack GC, Lamberty RGH. The arterial anatomy of skin flaps. Edinburgh: Churchill Livingstone; 1986.
26. Houseman ND, Taylor GI, Pan WR. The angiosomes of the head and neck: anatomic study and clinical applications. *Plast Reconstr Surg* 2000; 105: 2287–313.
27. Pils U, Anderhuber F. The external nose: the nasal arteries and their course in relation to the nasolabial fold and groove. *Plast Reconstr Surg* 2016; 138: 830.
28. Pils U, Anderhuber F, Neugebauer S. The facial artery-The main blood vessel for the anterior face? *Dermatol Surg* 2016; 42: 203–8.
29. Alferthofer MG et al. The Layered Anatomy of the Nose: An Ultrasound-Based Investigation. *Aesthet Surg J*. 2022 Mar 15; 42(4): 349–357.

*Надійшла до редакції 05.10.2023*

*Прийнята до друку 20.12.2023*

*Електронна адреса для листування dr.feinendegen@hin.ch*